

Ultrasound-guided subclavian vein cannulation in infants and children: a novel approach

T. Pirotte* and F. Veyckemans

Department of Anaesthesia, Université Catholique de Louvain, Cliniques universitaires St-Luc, Brussels, Belgium

*Corresponding author: Department of Anaesthesia, Université Catholique de Louvain, Cliniques universitaires St-Luc, Avenue Hippocrate 10-1821, 1200 Brussels, Belgium. E-mail: thierry.pirotte@clin.ucl.ac.be

Background. Central venous cannulation in infants remains challenging even for experienced paediatric anaesthesiologists. Ultrasound (US)-guidance techniques are proven to be safer for internal jugular vein catheterization. But the subclavian vein (SCV) is often the preferred site for long-term central venous catheterization in children. We describe a novel US-guided approach for SCV cannulation in infants and children.

Methods. The principle of this technique is to place the US probe at the supraclavicular level to obtain a longitudinal view of the SCV, and to gain access to the vein via the usual infraclavicular route to cannulate it under ultrasonic control. Details and pitfalls of this technique are described. The prospectively collected results of our first 25 punctures are reported.

Results. Patients' weight and age range were 2.2–27 kg and 1 day to 9 yr, respectively: 76% of the children weighed less than 10 kg. The success rate at the first attempt was 84% and 100% after two attempts. An asymptomatic thrombus in the SCV could also be detected with this technique.

Conclusions. This US-guided approach of the SCV offers a new possibility for central venous catheterization in children. This technique seems promising for children less than 10 kg and probably also for older children. It provides good quality needle guidance and allows to check the vessel patency before puncture.

Br J Anaesth 2007; **98**: 509–14

Keywords: children; monitoring, ultrasound; vein, subclavian

Accepted for publication: January 14, 2007

Central venous access in infants remains challenging even for experienced paediatric anaesthesiologists. Ultrasound (US)-guidance technique is becoming the gold standard for internal jugular vein (IJV) catheterization because it can both increase the success rate and decrease the complications related to central venous catheter (CVC) placement.^{1–5} The use of US-guidance for insertion of CVCs into the IJV in children is recommended since 2002 by the UK National Institute for Clinical Excellence (NICE).⁶ In a recent postal survey sent to paediatric anaesthetists in the UK, 90% of the responders had access to US, but less than 40% of them used it routinely.⁷ This may be due to the fact that the US-guidance technique is usually described as not usable for subclavian vein (SCV) cannulation in children, whereas SCV is often the preferred site for long-term CVC placement in children.⁸

In the literature, the classical landmark technique for SCV catheterization in children is associated with an incidence of arterial puncture and pneumothorax of up to 14%

and 6%, respectively.^{8–10} Moreover, young age (<6 months or even <1 yr) decreases success rate and increases complication rate.^{11 12}

When using US scanning for IJV cannulation, we found that the SCV can be easily visualized in the supraclavicular area. We therefore decided to perform a pilot study to evaluate a new approach for US-guided SCV catheterization. Here, we describe the results of our first 25 punctures.

Methods

With the approval of the departmental ethical committee, written informed consent was obtained from the parents before each procedure. During a 2-month period, the authors used this US-guided technique for all SCV catheterization in children less than 10 yr of age. The

only exclusion criterion was the inability to visualize the SCV correctly. All punctures were performed under Sevoflurane® general anaesthesia. Most of the children (approximately 75%) were only scheduled for CVC placement and were thus breathing spontaneously through a facemask.

Equipment

The structures to visualize are small and superficial, and room for the US probe is limited: a small probe with high frequency is thus needed. Linear probes are to be preferred because they do not distort the image the way curved probes do. We used a Sonosite Titan® US unit (Bothell, WA, USA) with its 10 MHz 2.5 cm linear ‘Hockey Stick’ Probe (HSP).

Principle of the technique

The US probe is placed at the supraclavicular level to obtain a longitudinal view of the SCV, while the needle gains access to the SCV via the classical infraclavicular route and catheterizes it under direct ultrasonic control (Fig. 1).

Positioning, US scanning, and SCV location

Children are placed in a light head-down position with their head in a neutral position. For infants, a rolled towel is placed transversally under the shoulders and the head is slightly turned away from the side of venipuncture in order to make room for the US probe. Turning the head to the side opposite to the puncture was limited because it has been shown to reduce significantly the cross-sectional area of the SCV.¹³

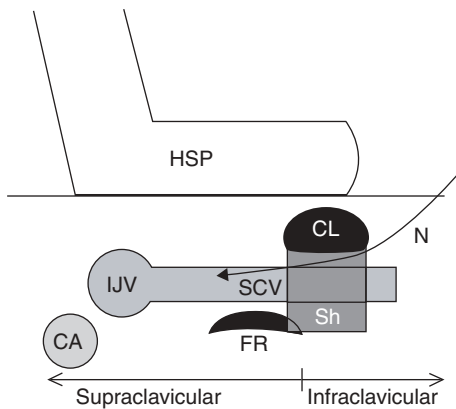


Fig 1 Principle of this technique. Needle (N) puncture and local infiltration are performed at the infraclavicular level, whereas the HSP placed at the supraclavicular level shows the underlying structures at this level. The needle can be seen passing through the anterior wall of the SCV which can be catheterized under direct vision in the direction of its confluent with the homolateral IJV. CL, clavicle; Sh, shadow; FR, first rib; CA, carotid artery.

The US unit is settled on its highest resolution with a depth of 1.8 cm for neonates and infants and a depth of 2.2 cm for children. Positioning should enable the anaesthetist to see the entire US picture and the patient’s landmarks without moving his head. This in-line view of anatomy and US image is mandatory for the hands–eyes coordination during the procedure. The HSP is placed at the supraclavicular level with its foot on the clavicle and the stick directed medially and slightly cranially (Fig. 2). Two bony structures are first recognized as bright hyperechoic structures with an acoustic shadow beneath them. The most superficial and lateral structure is the clavicle, whereas the first rib is deeper and more medial. The vascular structures are found passing between these two structures. To avoid targeting the wrong vessel, it is critical to be able to have a clear view of both the SCV and subclavian artery by slightly moving the probe.

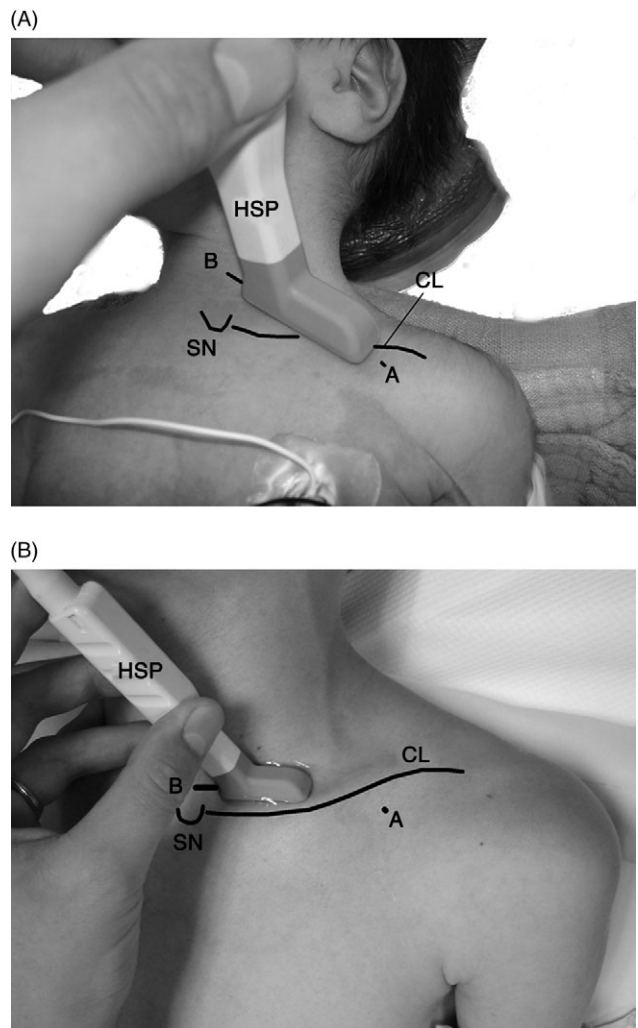


Fig 2 Different positioning of the US probe to obtain the best longitudinal view of the SCV in the two extremes of age in our series. (A) 1-day-old neonate (2.2 kg) and (B) 9-yr-old child (27 kg). HSP, ‘Hockey Stick’ Probe; CL, clavicle; SN, sternal notch; A, skin puncture site; B, surface marking obtained during US visualization of the vein: it shows the direction to be followed by the needle to hit the vein.

Downloaded from bjia.oxfordjournals.org at Serials Dept / Cornell University Medical Library on September 10, 2010

The SCV can be distinguished from the artery by the following characteristics:

- the SCV is in a more medial and superficial position;
- the SCV is not pulsating;
- the SCV varies its size with respiration;
- if followed medially the SCV reaches the IJV;
- there are valves in the lumen;
- a doppler can be used but is sometimes of limited quality with these small probes.

In small infants the length of the SCV, visualized from the clavicle to the IJV, is quite short (Fig. 3). This distance can be increased by slightly pulling the arm towards the knee. When the best picture of the SCV is obtained two surface marks are made (Fig. 2).

Mark A: The first mark is made at the middle of the foot-end of the US probe, at the infraclavicular level: this will be the entry point of the needle.

Mark B: The second mark is made at the other end of the probe showing the direction to be followed by the needle to reach the vein. The difference in probe orientation according to age is shown in Figure 2A and 2B.

Sterile puncture

Local anaesthesia is performed around the infraclavicular mark A. This infiltration will not hinder the US image of the SCV at the supraclavicular level. The probe together with some unsterile gel is inserted into a sterile probe cover (Dental-Drape[®] 8×170 cm Udo Heisig, Putzbrunn, Germany). Some sterile gel (Triad[®] 5 g, Brookfield, WI, USA) is applied between the probe cover and the skin. We used i.v. catheters for the initial puncture and catheterization: a 22G 25 mm catheter (Terumo[®] Europe, Leuven, Belgium) till the age of 2 yr and after that a 20G 48 mm catheter (BD Angiocath[®], Sandy, Utah,

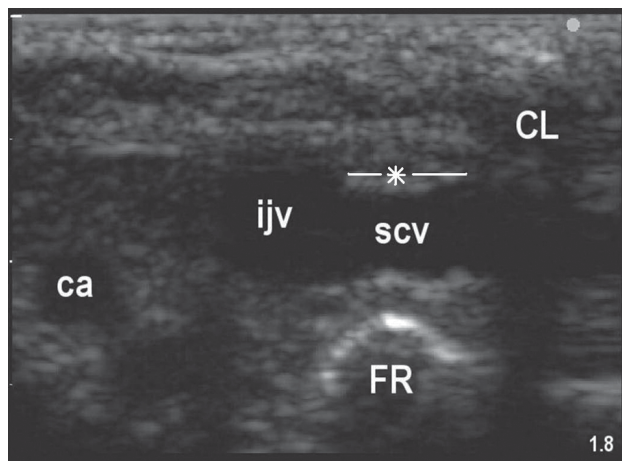


Fig 3 Ultrasonographic image obtained at the supraclavicular level in a 2.9 kg neonate. *Length of SCV visualized, this distance can be increased by pulling the arm downwards slightly. CL, clavicle; FR, first rib; SCV, subclavian vein; IJV, internal jugular vein; CA, carotid artery.

USA). The i.v. catheter is slightly bent in its centre to form an angle of 15–30°. The i.v. catheter pierces the skin at point A and is directed to the mark B. The US probe is then placed on the skin between the two surface markings and shows the needle in contact with the clavicle (Fig. 4A). At this point, it is crucial to check that the best view of the needle and of its target is obtained. The best longitudinal view of the SCV is obtained when its centre is scanned, giving a picture of its largest diameter and a sharp view of its walls.

In infants, the 2.5 cm long probe allows simultaneous visualization of the entire SCV and of the needle passing under the clavicle (Fig. 4A).

In older children this is not possible any more: the ultrasonic view is focused on the SCV (Fig. 2B) and the needle is advanced under the clavicle in order to pass strictly under the US probe. Although three-dimensional orientation is less easy, the procedure is not more difficult because the target to hit is larger.

In all cases, the i.v. catheter is seen passing through the anterior wall of the SCV which can be catheterized under direct vision in the direction of its confluence with the homolateral IJV (Fig. 4B). The needle is removed leaving the i.v. cannula in place and offering confirmation of a correct catheterization (Fig. 4C). After a positive aspiration of blood, the Seldinger technique is used through these catheters. A 0.021-inch diameter guide wire will pass through the 22G catheter, whereas a 0.025 inch will need the 20G catheter to pass.

Data analysis

In this observational study, we prospectively recorded data regarding weight and age of the children, puncture side, success rate, and complications. Weight and age will be expressed in range, mean, median, upper and lower quartile (Statistica). ‘Ultimate success’ was defined as the possibility to introduce the guide wire in the SCV. An ‘attempt’ was defined as each needle advancement under the clavicle in order to hit the vein. Complications as arterial puncture, pneumothorax, and haematoma were recorded.

Results

During this 2-month period, 25 SCV were punctured in 23 children with this technique. All SCV could be easily visualized from the supraclavicular level, so no children had to be excluded. Demographic data are shown in Table 1: 76% of the patients weighing less than 10 kg (40% less than 3.5 kg) and 67% of them having less than 1 yr of age (48% less than 3 months). Two infants (2.8 and 2.9 kg) were punctured at both sides within a 2-week interval because of catheter obstruction.

Ultimate success was 100% and in 84% of the cases only one attempt was required. More than two attempts

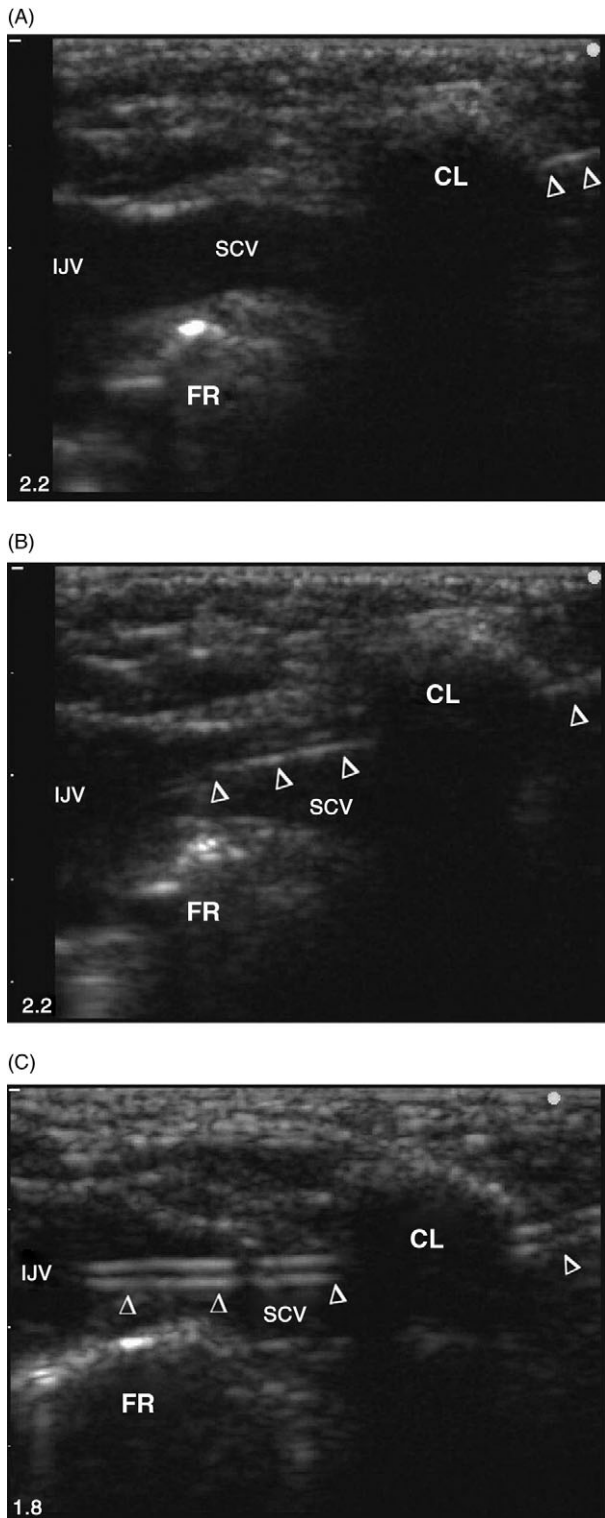


Fig 4 Puncture technique in an infant. (A) A 22G (25 mm) i.v. catheter passing under the clavicle, a longitudinal view of both needle and SCV is obtained before needle progression. (B) The needle punctures the SCV and progresses under direct vision in the lumen of the vein. (C) After removal of the needle the i.v. cannula is catheterized and confirmed to be within the SCV almost reaching its confluence with the homolateral IJV. CL, clavicle; FR, first rib; SCV, subclavian vein; IJV, internal jugular vein; Δ : 22G, 25 mm i.v. catheter: needle in cannula (A and B), needle out (c).

Table 1 Demographic data of the patients

	Weight (kg)	Age
Range	2.2–27	1 day–9 yr
Mean	8.3	1.7 yr
Median	6.1	4 months
Lower quartile	2.9	1.5 months
Upper quartile	8.6	1.8 yr

were never needed and the mean number of attempts per patient was 1.2. The left SCV was more often cannulated (67%) because of the right handed anaesthetist but no more attempts were needed when the right SCV was punctured. We had no arterial puncture, no haematoma, and no pneumothorax in this series, although it was also our learning curve for this technique.

A second attempt was needed in four cases, the reasons for this are briefly described hereafter.

- (i) In a 2.7 kg infant, the SCV was catheterized by the first attempt but during guide wire manipulation the vein was ‘lost’ and a second SCV puncture was needed.
- (ii) In a 2.9 kg infant, bony contact was felt during needle advancement. US did not give a complete view of the needle and failed to visualize this contact with the bony structure (probably the first rib). The needle was withdrawn and redirected strictly under the long axis of the US probe with success.
- (iii) In a 6.1 kg infant, the bevel of the needle could clearly be seen into the SCV but after withdrawing the needle no blood could be withdrawn from the i.v. cannula. The needle tip had probably entered the vein but not enough to be catheterized. With the second attempt, the needle was catheterized further in the direction of the homolateral IJV.
- (iv) In a 2-yr-old child, the SCV was found to have a very steep direction after its passage over the first rib joining the IJV far under the clavicle. The visualization in long axis of the entire SCV was made difficult and two attempts were needed to combine needle and SCV visualization.

Moreover in this series, a asymptomatic thrombus in the left SCV was detected before puncture in a 7-month-old infant who had already had SCV catheterization in the past (Fig. 5).

Discussion

To our knowledge, this is the first study that describes US-guidance for SCV catheterization in children. One paper reports the use of US to puncture SCV in children but neither details regarding the technique, nor success and complication rates are given.¹⁴ Moreover, the vein is punctured much more laterally and is thus an ‘axillary’ vein puncture and not a real SCV puncture. Even in the

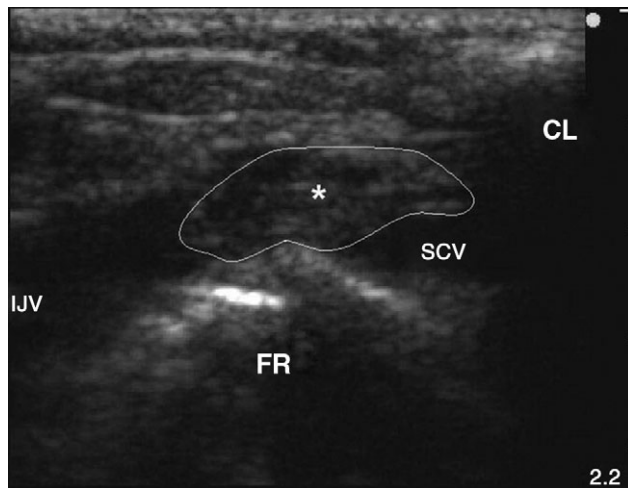


Fig 5 Illustration of a subclavian thrombosis in a 7-month-old infant (6.2 kg). CL, clavicle; FR, first rib; SCV, subclavian vein; IJV, internal jugular vein; *thrombus.

adult population, only a few articles have reported US-guidance for axillary vein puncture. In two studies, both the vein and the needle are imaged transversally which offers a poorer needle visualization.^{15 16} One paper described a more lateral approach of the axillary vein where a longitudinal visualization of both the vein and needle was possible.¹⁷ This interesting approach where needle visualization is enhanced can unfortunately not be applied to infants because of the lack of room for both the US probe and the needle in the infraclavicular area. At the present time, as Hind and colleagues¹⁸ already showed in his meta-analysis, limited evidence favours two-dimensional US-guidance compared with the landmark method for SCV punctures in adults.

Our longitudinal in-line puncture technique offers a nice view of both the needle and the vein;¹⁹ this probably contributes to the good results. All subclavian central venous lines could indeed be placed at the chosen side without complication. More than two attempts, which has been advocated as a criteria increasing the incidence of complications,¹¹ were never needed. In 84% of the cases, the SCV was catheterized at the first attempt. Venous haematomas due to multiple failed attempts to catheterize the vein were thus not seen in this series. These haematomas compress the vein reducing progressively its diameter and making the next punctures more difficult.

These results are comparable with those of US-guidance techniques for IJV puncture in children.²⁻⁴ For some authors, infants weighing less than 10 kg or younger than 1 yr still remain quite difficult to puncture even with US-guidance.^{5 20} We did not experience this problem in our series in which the majority of the patients were younger than 1 yr of age or weighing less than 10 kg (67% and 76%, respectively). This could be explained by the following anatomical considerations.

The first is that the SCV is fixed to the clavicle avoiding its anterior wall to collapse under the pressure of the approaching needle. This phenomenon, frequently seen when US-guidance is used for IJV puncture in infants, leads to transfixion of the vein, venous haematoma, or failed puncture.

The second is that in infants less than 1 yr of age, the SCV runs more cephalad than in older children; having a nearly 'extrathoracic' position before reaching the innominate vein.²¹ The whole length of the vein is therefore more easily visualized by US in infants than in children. Moreover, the place where the SCV passes over the first rib has been defined as a 'safe spot' for its cannulation.²² At that place, the first rib protects the lung from accidental puncture and from this place on the subclavian artery takes a different direction than the SCV, passing behind the anterior scalene muscle whereas the vein passes in front of it.

Puncture time was not measured in this study. As we know US-guided techniques, compared with landmark technique, needs some preparation time. With experience, anatomical screening and equipment preparation time, however, should not exceed 5 min. Because the anatomical (vein position) and pathological (vein thrombosis) variations are now diagnosed by US, time from skin puncture to guide wire placement is made much shorter. And the very time-consuming vicious circle of multiple attempts, venous, or arterial haematoma, failed puncture, and need to change to another CVC insertion site is probably disappearing with the use of US-guidance.

Another advantage of US is the early detection of wrong way guide wire catheterization. If no arrhythmias are produced or if a resistance is felt during guide wire advancement, the US probe can be used to scan the distal part of the ipsilateral IJV.²³ If the guide wire is seen in the IJV, it can be withdrawn until it disappears from the IJV lumen and redirected towards the heart. The probe can also be used to compress the IJV and prevent guide wire misplacement at a second attempt.

In a complete sterile setting, the assistance of a 'third hand' is usually not needed because the probe can be left on the sterile field during manoeuvres that need two hands such as clavicle palpation for needle insertion or guide wire advancement.

The use of US does not only provide needle guidance but also checks the patency of the SCV in children who have already had SCV catheterization in the past. We should indeed have in mind that the reported incidence of catheter-related thrombosis in children is as low as 5% in studies including only symptomatic cases, but reaches 50% in studies where patients are systematically screened for catheter-related thrombosis.²⁴

The learning curve of this approach, as for every US-guided technique, will probably be highly operator-dependant. The operator's experience in SCV punctures in children and the number performed per year will also be a

factor to be taken into account. At the time of the study, the authors had a 14-month experience of US-guided techniques for vascular and locoregional techniques in adults and children. Moreover, they had also a large experience in landmark technique for SCV puncture in children, performing together between 150 and 200 punctures per year. The use of an appropriate equipment, especially a high-frequency paediatric probe, seems mandatory to achieve a high success rate.

In conclusion, this US-guided approach for SCV catheterization offers a new possibility for central venous access in infants to paediatric anaesthesiologists. It shows a nice view of the underlying anatomy, its variations, and its possible pathologies (thrombosis). According to this first series of patients, the technique seems promising for children less than 10 kg and probably also for older children. More prospective and comparative studies are therefore needed to define its learning curve for an anaesthetist not experienced in using US and to prove its advantage over the classic landmark technique.

Acknowledgements

The author thanks Professor P. Clapuyt, Dr C. Saint-Martin, and Dr R. Menten (Department of Paediatric Radiology, Université Catholique de Louvain, Brussels, Belgium) for their precious advice about sono-anatomy and safe ultrasound-guided punctures.

References

- 1 Alderson PJ, Burrows FA, Stemp LI, et al. Use of ultrasound to evaluate internal jugular vein anatomy and to facilitate central venous cannulation in paediatric patients. *Br J Anaesth* 1993; **70**: 145–8
- 2 Verghese ST, McGill WA, Patel RI, et al. Ultrasound-guided internal jugular vein cannulation in infants: a prospective comparison with the traditional palpation method. *Anesthesiology* 1999; **91**: 71–7
- 3 Verghese ST, McGill WA, Patel RI, et al. Comparison of three techniques for internal vein cannulation in infants. *Paediatr Anaesth* 2000; **10**: 505–11
- 4 Asheim P, Mostad U, Aadahl P. Ultrasound-guided central venous cannulation in infants and children. *Acta Anaesthesiol Scand* 2002; **46**: 390–2
- 5 Leyvi G, Taylor DG, Reith E, et al. Utility of ultrasound-guided central venous cannulation in pediatric surgical patient: a clinical series. *Paediatr Anaesth* 2005; **15**: 953–8
- 6 National Institute for Clinical Excellence. Guidance on the Use of Ultrasound Location Devices for Placing Central Venous Catheters. Technology Appraisal Guidance No 49, September 2002, <http://www.nice.org.uk> 2002
- 7 Bosman M, Kavanagh RJ. Two dimensional ultrasound guidance in central venous catheter placement; a postal survey of the practice and opinions of consultant pediatric anesthetists in the United Kingdom. *Paediatr Anaesth* 2006; **16**: 530–7
- 8 Citak A, Karabocuoglu M, Utsel R, et al. Central venous catheters in pediatric patients—subclavian venous approach as the first choice. *Pediatr Int* 2002; **44**: 83–6
- 9 Casado-Flores J, Valdivielso-Serna A, Pérez-Jurado L. Subclavian vein catheterization in critically ill children: analysis of 322 cannulations. *Int Care Med* 1991; **17**: 350–4
- 10 Chul-Woo J, Jae-Hyon B, Myung-Won K, et al. Head position for facilitating the superior vena caval placement of catheters during right subclavian approach in children. *Int Care Med* 2002; **30**: 297–9
- 11 Venkataraman ST, Orr RA, Thompson AE. Percutaneous infraclavicular subclavian vein catheterization in critically ill infants and children. *J Pediatr* 1987; **113**: 480–4
- 12 Finck C, Smith S, Jackson R, et al. Percutaneous subclavian central venous catheterization in children younger than one year of age. *Am surg* 2002; **68**: 401–4
- 13 Lukish J, Valladars E, Rodriguez C, et al. Classical positioning decreases subclavian vein cross-sectional area in children. *J Trauma* 2002; **53**: 272–5
- 14 Kaye R, Sane SS, Towbin RB. Pediatric intervention: an update—part 2. *J Vasc Interv Radiol* 2000; **11**: 807–22
- 15 Gualtieri E, Deppe SA, Sipperly ME, et al. Subclavian venous catheterization: greater success rate for less experienced operators using ultrasound guidance. *Crit Care Med* 1995; **23**: 692–7
- 16 Sharma A, Bodenham AR, Mallick A. Ultrasound-guided infraclavicular axillary vein cannulation for central venous access. *Br J Anaesth* 2004; **93**: 188–92
- 17 Sandhu NS. Transpectoral ultrasound-guided catheterization of the axillary vein: an alternative of standard catheterization of the subclavian vein. *Anesth Analg* 2004; **99**: 183–7
- 18 Hind D, Calvert N, McWilliams R, et al. Ultrasonic locating devices for central venous cannulation: meta-analysis. *Br Med J* 2003; **327**: 361–7
- 19 Chapman GA, Johnson D, Bodenham AR. Visualisation of needle position using ultrasonography. *Anaesthesia* 2006; **61**: 148–58
- 20 Arai T, Yamashita M. Central venous catheterization in infants and children—small calibre audio-Doppler versus ultrasound scanner. *Paediatr Anaesth* 2005; **15**: 858–61
- 21 Groff DB, Ahmed N. Subclavian vein catheterization in the infant. *J Pediatr Surg* 1974; **9**: 171–4
- 22 Cobb LM, Vinocur CD, Wagner CW, et al. The central venous anatomy in infant. *Surg Gynecol Obstet* 1987; **165**: 231–4
- 23 Howes B, Dell R. Ultrasound to detect incorrect guidewire positioning during subclavian line insertion. *Anaesthesia* 2006; **61**: 615
- 24 Revel-Vilk S. Central venous line-related thrombosis in children. *Acta Haematol* 2006; **115**: 201–6